

Vaping tetrahydrocannabinol unmasks Brugada pattern and induces ventricular fibrillation in Brugada syndrome: a case report

Amith Seri ^{1,2}, Pattara Rattanawong ¹, Tina Firouzbakht¹, and Dan Sorajja ^{1*}

¹Department of Cardiology, Mayo Clinic, 5777 East Mayo Boulevard, Phoenix, AZ 85054, USA; and ²Department of Internal Medicine, McLaren Regional Medical Center, Flint, MI, USA

Received 12 January 2022; first decision 2 February 2022; accepted 9 May 2022

For the podcast associated with this article, please visit <https://academic.oup.com/ehjcr/pages/podcast>

Background

Fever, alcohol, and sodium channel blockers can unmask Brugada pattern and may also induce arrhythmias in Brugada syndrome. We report a case of unmasked Type-1 Brugada pattern presenting with ventricular fibrillation that was induced by a tetrahydrocannabinol vaping.

Case summary

A 48-year-old male with a past medical history of hypertension treated with hydrochlorothiazide and back pain controlled with tetrahydrocannabinol vaping presented with sudden cardiac arrest from ventricular fibrillation, which was terminated with defibrillation. Electrocardiogram after resuscitation showed a new Type-1 Brugada pattern compared to a previous normal baseline electrocardiogram. Echocardiography and coronary angiogram were unremarkable. Complete blood count and chemistries were unremarkable except for mild hypokalaemia ($K = 3.3$ mmol/L). After correction of the hypokalaemia, the Type-1 Brugada pattern persisted. Urine drug screen was positive for tetrahydrocannabinol (60 ng/mL). Genetic testing was negative for inherited arrhythmic disease and cardiomyopathy gene panels.

Discussion

The patient's type-1 Brugada pattern and ventricular fibrillation were likely induced by vaping tetrahydrocannabinol. He underwent secondary prevention with an implantable cardioverter-defibrillator. He abstains from cannabis and Type-1 Brugada pattern is normalized. There was no arrhythmic event at his 18-month follow-up appointment with abstinence from tetrahydrocannabinol.

Keywords

Brugada syndrome • Tetrahydrocannabinol • Ventricular fibrillation • Unmasking • Case report

ESC Curriculum

5.6 Ventricular arrhythmia • 7.2 Post-cardiac arrest • 5.8 Cardiac ion channel dysfunction • 5.10 Implantable cardioverter defibrillators

Learning points

- Tetrahydrocannabinol can unmask Brugada syndrome and induce ventricular fibrillation.
- Tetrahydrocannabinol may induce fatal arrhythmia in Brugada syndrome regardless of the routes of administration.

* Corresponding author. Email: Sorajja.dan@mayo.edu

Handling Editor: Christopher Wong

Peer-reviewers: Silvia Castelletti and Fabien Barbieri

Compliance Editor: Megha Agarwal

Supplementary Material Editor: Mariame Chakir

© The Author(s) 2022. Published by Oxford University Press on behalf of the European Society of Cardiology.

This is an Open Access article distributed under the terms of the Creative Commons Attribution-NonCommercial License (<https://creativecommons.org/licenses/by-nc/4.0/>), which permits non-commercial re-use, distribution, and reproduction in any medium, provided the original work is properly cited. For commercial re-use, please contact journals.permissions@oup.com

Introduction

Brugada syndrome is an autosomal dominant inherited cardiac arrhythmic disease associated with malignant ventricular arrhythmias and sudden cardiac death, more prevalent in the Asian population. The characteristic electrocardiogram (ECG) pattern of coved-type ST segment elevation ≥ 2 mm in the right precordial leads is diagnostic.¹ The ECG pattern may often be hidden and only revealed after exposures to certain conditions like fever, intoxication (alcohol, cannabis, cocaine), vagal stimulation, electrolyte imbalance, anaesthetics, psychotropic agents, and sodium channel blockers.² Cannabis, containing tetrahydrocannabinol (THC), has become one of the most commonly used drugs given its widespread legalization in the past decade.³ Vapourized cannabis produces significantly greater effects, cognitive and psychomotor impairment, and higher blood THC concentrations when compared with the same doses of smoked cannabis.⁴ These findings have implications for users believing vapourization to be a safer route of administration. Previous case reports demonstrated that Brugada pattern can be unmasked by THC ingestion⁵ and THC smoking.^{6,7} However, Brugada syndrome unmasked by THC vapourization has not been reported.

Timeline

Date	Event
Day 0	<ul style="list-style-type: none"> Out-of-hospital sudden cardiac arrest with ventricular fibrillation required defibrillation. ECG showed type-1 Brugada pattern. CT head was negative for acute intracranial abnormality. Chest X-ray was unremarkable. CT angiogram was negative for pulmonary embolism. Labs were normal except for mild hypokalaemia. Urine drug screen was positive for THC.
Day 1	<ul style="list-style-type: none"> Cardiac angiogram showed normal coronaries. Hypokalaemia was corrected. ECG continued to show type-1 Brugada pattern. ICD implantation.
Day 2	<ul style="list-style-type: none"> Discharged.
Follow-up at 3 and 18 months	<ul style="list-style-type: none"> ECG without Type-1 Brugada pattern. No arrhythmic events.

Case presentation

A 48-year-old Caucasian man with a known history of hypertension and factor V Leiden deficiency was admitted to our hospital after suffering

from sudden cardiac arrest while at home sitting on the couch after THC vapourization. He initially developed tingling and numbness in his hands followed by a syncopal episode with agonal respiration which was witnessed by his wife. Paramedics arrived six minutes later and noted his cardiac rhythm to be in polymorphic ventricular tachycardia (Figure 1A). Defibrillation was delivered with 200 Joules, and a single dose of IV lidocaine was given at the scene by emergency medical services. Return of spontaneous circulation was achieved. He regained consciousness and was able to maintain his airway without intubation. His rhythm was noted to be back in normal sinus, but there was evidence of Type-1 Brugada pattern (Figure 1B).

On admission to our hospital, physical examination was unremarkable, and vital signs were blood pressure of 150/130 mmHg, heart rate of 120 bpm, and respiratory rate of 23 breaths per minute with an oxygen saturation of 95% at room air. Labs were significant for mild hypokalaemia ($K = 3.3$ mmol/L) and urine test positive for THC (60 ng/mL, normal ≤ 3 ng/mL⁸). High-sensitive troponin-T and complete blood count were unremarkable. Initial ECG showed sinus tachycardia with Type-1 Brugada pattern in right precordial leads (Figure 2A). Transthoracic echocardiogram was noted to be normal with an ejection fraction of 62% without any wall motion abnormalities. Computed tomography (CT) of the head ruled out any intracranial abnormality. CT angiogram of the chest was negative for pulmonary embolism. A coronary angiogram showed no evidence of significant coronary artery disease. Exercise stress test for atypical chest pain and shortness of breath on exertion a month before hospitalization was negative for ischaemia. A repeat ECG after correction of his hypokalaemia ($K = 4.5$ mmol/L), on following day at 15 h after initial presentation, continued to show type-1 Brugada pattern (Figure 2B).

His past medical history was significant for a syncopal episode after playing basketball 20 years prior to his current presentation. At that time, he was noted to have agonal respiration as well. Family history includes sudden cardiac death in his maternal uncle at age of 55 years old. Twelve-lead ECG was performed in his mother, maternal half-brother, and maternal half-sister which all negative for Brugada pattern. The patient is not in-contact with biological father. Patient had been using THC vapourization for his back pain of musculoskeletal origin for the past 8 years. He had been taking hydrochlorothiazide for hypertension and takes no other medication.

Given the history of cardiac syncope, sudden cardiac arrest, and type-1 Brugada pattern on the ECG, Brugada syndrome was diagnosed, and the implantable cardioverter-defibrillator (ICD) was implanted before hospital discharge for secondary prevention. A comprehensive genetic panel analysis of 67 genes associated with inherited arrhythmic and cardiomyopathy diseases was performed⁹ and subsequently revealed no associated mutation. Given a long half-life of THC (67 days),⁸ a repeat ECG was performed at 3 months after abstinence of THC which showed normal sinus rhythm without Brugada pattern (Figure 2C). After 18 months of follow-up, he has been abstinent from THC and has reported no arrhythmic events.

Discussion

Brugada syndrome is an inherited arrhythmic disease, associated with an increased risk of ventricular fibrillation, and sudden cardiac death.

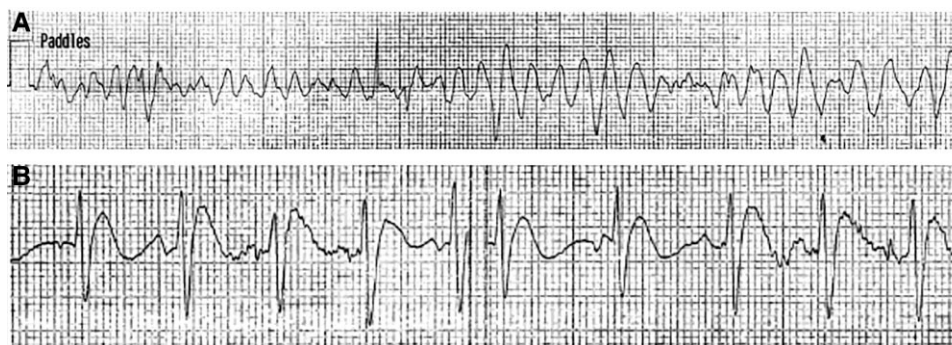

Figure 1 (A) Polymorphic ventricular tachycardia and (B) Type-1 Brugada pattern.

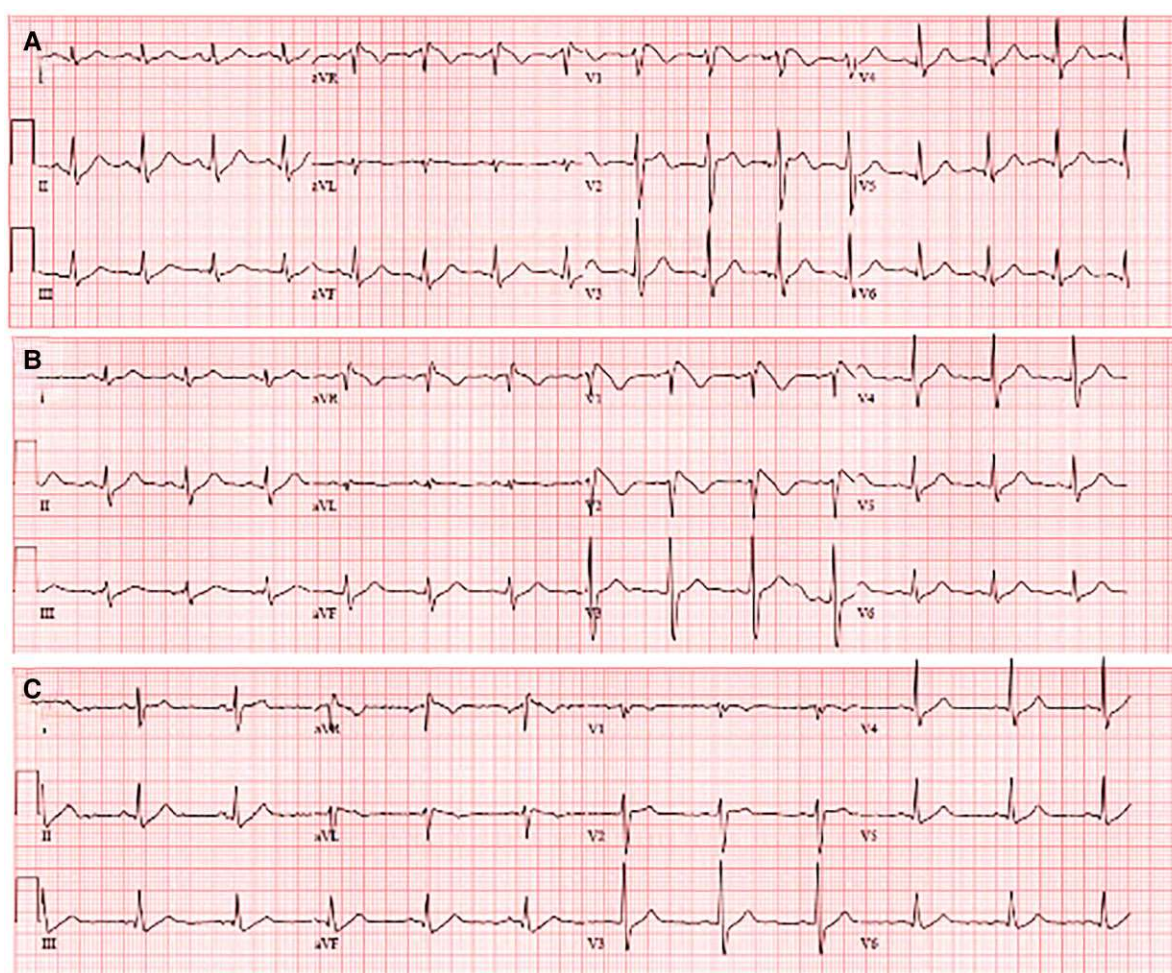


Figure 2 (A) Sinus tachycardia with Type-1 Brugada pattern in right precordial leads, (B) persisted Type-1 Brugada pattern after potassium normalized, and (C) A repeat electrocardiogram at 3 months after abstinence of tetrahydrocannabinol showed normal sinus rhythm without Brugada pattern.

Brugada syndrome may manifest as syncope, agonal respiration, or sudden cardiac arrest. However, the majority of the patients can be asymptomatic. Characteristic Type-1 Brugada ECG pattern may sometimes be concealed but unmasked in the presence of specific

conditions such as fever, electrolyte imbalance, intoxication, psychiatric medications, and sodium channel blockers.²

Cannabis use has drastically increased given the changes in the policy and regulation of the drug throughout the world. Vaping has

emerged as a popular method for cannabis administration under the notion that it is associated with less toxicant exposure compared to traditional smoking and ingestion. However, Spindle et al.⁴ reported that inhaling an equivalent dose of vapourized cannabis compared to smoking led to greater plasma levels of THC, cognitive and psychomotor effects, and significantly greater increases in heart rate.

Most of the cardiovascular risks associated with cannabis have been studied in people with smoking and ingestion as the route of administration. A systemic review done by Richards et al.¹⁰ highlighted several clinical studies, case series, and reports which showed an association between cannabis use and arrhythmias. The arrhythmogenic potential of THC included sinus tachycardia, sinus bradycardia, second-degree atrioventricular block, and atrial fibrillation. There are several reported cases showing an association between cannabis and Brugada pattern.^{5–7,11–14} Two cases reported THC as possible triggers of ventricular fibrillation in Brugada syndrome,^{7,14} similar to our patient. Our case emphasizes the potentially fatal and malignant effects of THC on Brugada syndrome patients; however, the mechanism of THC-induced Brugada pattern is unclear. Sympathetic activation and parasympathetic inhibition are observed with the low to moderate doses THC; however, at higher doses, sympathetic output is inhibited and parasympathetic output is increased.¹⁵ The arrhythmic effect of THC in Brugada syndrome may be explained by action potential shortening and vagal tone hyperstimulation. Another proposed mechanism was the possibility of inhibition of voltage-gated sodium ion channels by THC.¹² Urine THC concentration in our patient (60 ng/mL) was 20 times higher than normal limit (3 ng/mL). Dose-dependent vagal stimulation and THC dose accumulation due to long half-life may explain acute arrhythmic event in a chronic THC user. The ventricular fibrillation in previous case report was also documented in a chronic THC user, similar to our patient.⁷

We do not have documented evidence of hypokalaemia from the previous syncope episode 20 years prior to presentation. However, by patient's history, sport-related vagal tone likely played a major role for the syncope and agonal respiration. Meanwhile, it is possible that trigger of ventricular fibrillation in our patient is multifactorial given the hypokalaemia at presentation. However, Type-1 Brugada pattern persisted despite hypokalaemia correction. Therefore, THC-related increased vagal tone was the most likely the main trigger of ventricular fibrillation in our case. Lidocaine could potentially unmask Brugada pattern. However, our patient received one bolus dose of IV lidocaine during the resuscitation. Because the half-life of lidocaine is less than 2 h, the persistence of Brugada pattern after 15 h after the resuscitation was unlikely from lidocaine.

There is limited data studying the cardiac effects with THC vapourization. We report that the THC vapourization can unmask Brugada syndrome and induce ventricular fibrillation. For patients with Brugada syndrome, fatal arrhythmic events can be triggered by THC regardless of the route of administration. This case highlights THC as a potential agent that can unmask Type-1 Brugada ECG pattern and also has the ability to trigger major arrhythmic events in these patients regardless of the route of administration. This case underscores the importance and need to increase awareness about the potential harmful effects of THC in Brugada syndrome patients.

Lead author biography



Amith Seri is currently a first year Internal Medicine Resident at McLaren Regional Medical Center/ Michigan State University. He graduated from Osmania Medical College in India. He is interested in pursuing a Cardiology Fellowship.

Consent: The authors confirm that written consent for submission and publication of this case report including images and associated text has been obtained from the patient in line with COPE guidelines.

Conflict of interest: None declared.

Funding: This research did not receive any specific grant from funding agencies in the public, commercial, or not-for-profit sectors.

References

- Vutthikraivit W, Rattanawong P, Putthapiban P, Sukhumthamarat W, Vathesatogkit P, Ngarmukos T, Thakkinian A. Worldwide prevalence of Brugada syndrome: a systematic review and meta-analysis. *Acta Cardiol Sin* 2018;**34**:267–277.
- Antzelevitch C, Yan GX, Ackerman MJ, Borggreffe M, Corrado D, Guo J, Gussak I, Hasdemir C, Horie M, Huikuri H, Ma C, Morita H, Nam GB, Sacher F, Shimizu W, Viskin S, Wilde AAM. J-Wave syndromes expert consensus conference report: emerging concepts and gaps in knowledge. *Heart Rhythm* 2016;**13**:e295–324.
- World Drug Report 2019 (United Nations publication, Sales No. E.19.XI.8). Available from: https://wdr.unodc.org/wdr2019/prelaunch/WDR19_Booklet_5_CANNABIS_HALLUCINOGENS.pdf (08 February 2022).
- Spindle TR, Cone EJ, Schlienz NJ, Mitchell JM, Bigelow GE, Flegel R, Hayes E, Vandrey R. Acute effects of smoked and vaporized cannabis in healthy adults who infrequently use cannabis: a crossover trial. *JAMA Netw Open* 2018;**1**:e184841.
- Jo NY, Chu CC, Ramsey BC. Brugada electrocardiogram pattern induced by recreational delta-8-tetrahydrocannabinol (THC): a case report. *Cureus* 2021;**13**:e19058.
- Kariyana PT, Jayarangaiah A, Hegde S, D.Marmur J, Wengrofsky P, Yacoub M, Post M, I. McFarlane S. Marijuana induced type I Brugada pattern: a case report. *Am J Med Case Rep* 2018;**6**:134–136.
- Doctorian T, Chou E. Cannabis-induced Brugada syndrome presenting as cardiac arrest. *J Cardiol & Cardiovasc Ther* 2017;**6**:555678.
- Huestis MA, Henningfield JE, Cone EJ. Blood cannabinoids. I. Absorption of THC and formation of 11-OH-THC and THCCOOH during and after smoking marijuana. *J Anal Toxicol* 1992;**16**:276–282.
- Invitae. Invitae Arrhythmia and Cardiomyopathy Comprehensive Panel. 2021. Available from: <https://www.invitae.com/en/providers/test-catalog/test-02101> (08 February 2022).
- Richards JR, Blohm E, Toles KA, Jarman AF, Ely DF, Elder JW. The association of cannabis use and cardiac dysrhythmias: a systematic review. *Clin Toxicol (Phila)* 2020;**58**:861–869.
- Alonso JV, Teo BH, Pozo FJ, Aguayo MA, Sanchez A. Brugada electrocardiogram pattern induced by cannabis; is cannabis safe? *Am J Emerg Med* 2016; **34**:1738.e1–1738.e4.
- Daccarett M, Freih M, Machado C. Acute cannabis intoxication mimicking bruGada-like ST segment abnormalities. *Int J Cardiol* 2007;**119**:235–236.
- Romero-Puche AJ, Trigueros-Ruiz N, Cerdan-Sanchez MC, Pérez-Lorente F, Roldán D, Vicente-Vera T. Brugada electrocardiogram pattern induced by cannabis. *Rev Esp Cardiol (Engl Ed)* 2012;**65**:856–858.
- Stockholm SC, Rosenblum A, Byrd A, Mery-Fernandez E, Bhandari M. Cannabinoid-induced brugada syndrome: a case report. *Cureus* 2020;**12**:e8615.
- Ghuran A, Nolan J. Recreational drug misuse: issues for the cardiologist. *Heart* 2000; **83**:627–633.